Chapter 3 Development and Morphology of Normal Lymphocytes

Mindray Morphology Corner | Series Course-II WBC

The Journey from "Immature Recruits" to "Mature Immune Soldiers"

If we compare the human immune system to an army, lymphocytes are undoubtedly one of its most important special forces.
They are responsible for recognizing pathogens, eliminating infected cells, producing antibodies, and even remembering previously encountered enemies. Although lymphocytes are the smallest cells in the WBC of peripheral blood smears, they actually perform highly complex and essential immune functions.
For anyone beginning to study hematologic morphology, understanding how lymphocytes develop from immature cells into mature immune cells is an important foundation for learning about abnormal lymphocytes, viral infections, and hematologic diseases.
Today, we will explore the development and morphology of normal lymphocytes in a simple and engaging way.

I. Where Do Lymphocytes Come From?
All blood cells originate from hematopoietic stem cells in the bone marrow.
Some hematopoietic stem cells gradually differentiate into cells of the lymphoid lineage, which eventually develop into lymphocytes. During this process, lymphoid cells undergo several maturation stages, including lymphoblasts, prolymphocytes, and mature lymphocytes.
Among mature lymphocytes, T lymphocytes further mature in the thymus, while B lymphocytes mainly mature in the bone marrow before entering the peripheral blood and lymphoid
tissues.

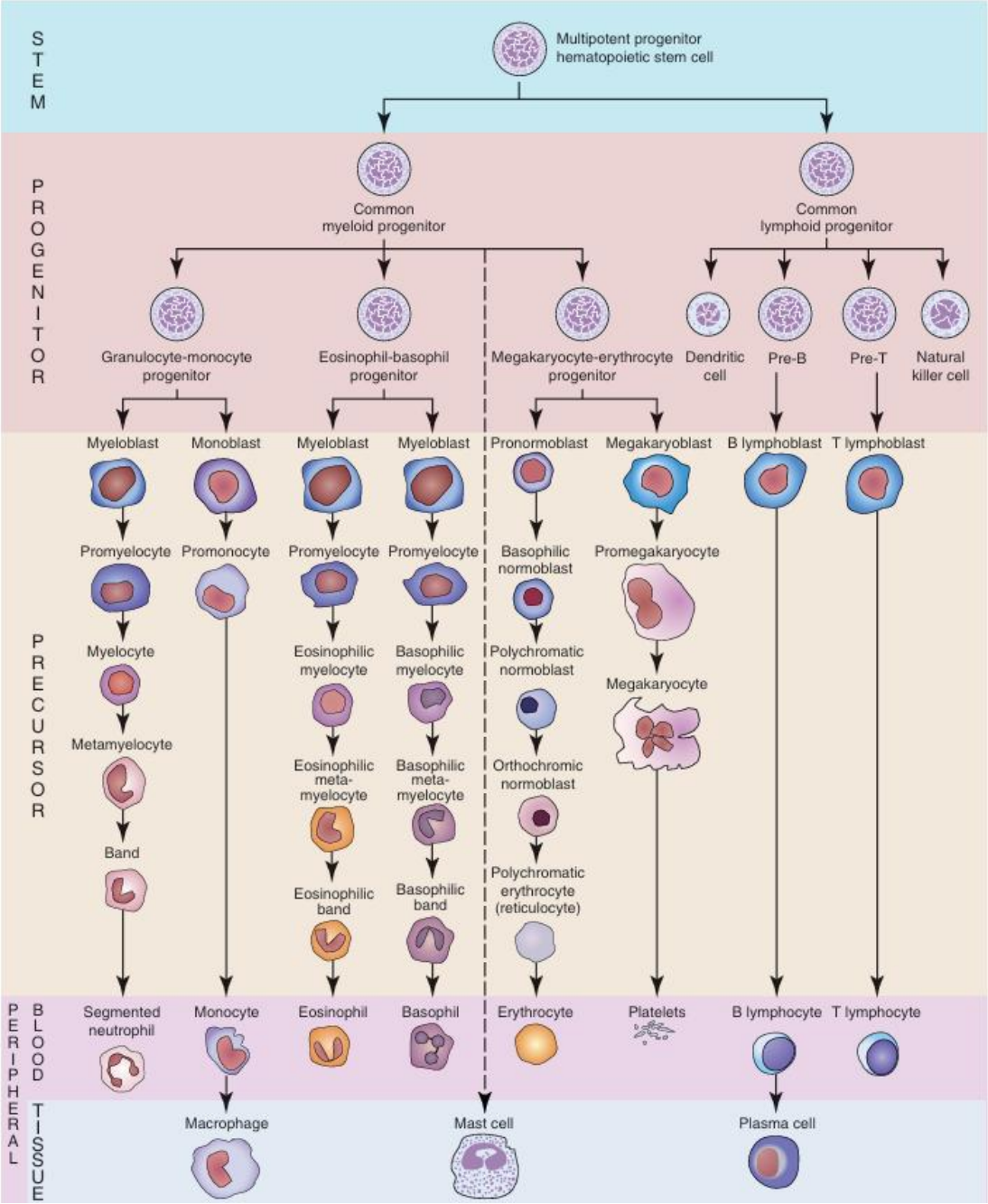

Figure 1: Chart of hematopoiesis.[1]

The developmental pathway of lymphocytes can be summarized as follows:

- Hematopoietic stem cell → Lymphoblast → Prolymphocyte → Mature lymphocyte → T lymphocyte / B lymphocyte

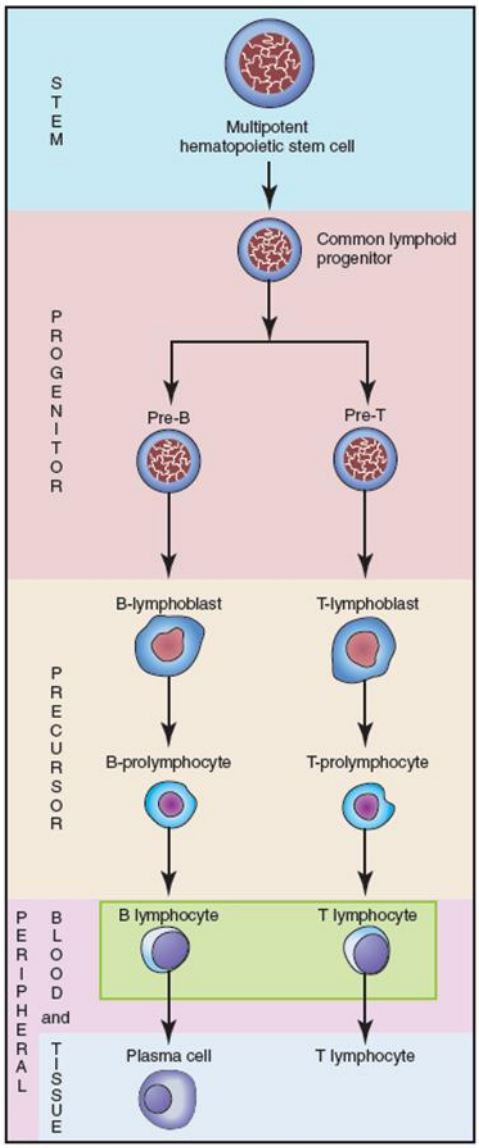

Figure 2: The maturation of Lymphocytes [1]

Among them:

- ✓ T lymphocytes migrate to the thymus for further maturation;
- ✓ B lymphocytes mainly mature within the bone marrow.

After maturation, they enter the peripheral blood and lymphoid tissues to carry out immune functions.

II. Lymphoblasts: Newly Born "Recruits"

Lymphoblasts represent one of the earliest recognizable stages of lymphoid development. Under normal conditions, they are mainly found in the bone marrow and are rarely seen in the peripheral blood. Lymphoblasts are rarely seen in normal peripheral blood; their increased presence may indicate acute lymphoblastic leukemia.

1. Morphological Features of Lymphoblasts

When observing lymphoblasts for the first time, many people have the same impression: "This cell looks very immature."

This "immature" appearance mainly comes from the nucleus.

(1) Relatively large cell size

The diameter is usually around 10–18 μm.

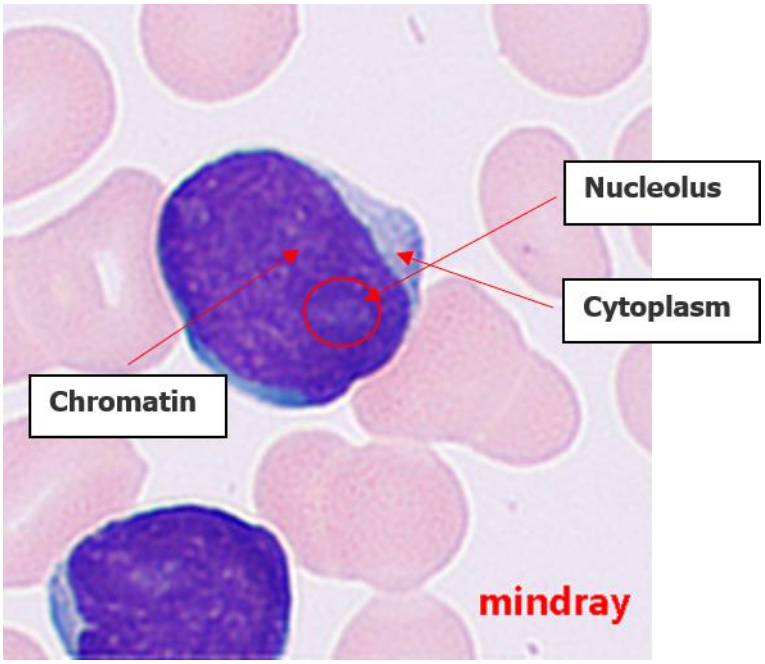

Figure 3: The morphology of Lymphoblasts

Compared with mature lymphocytes, lymphoblasts are noticeably larger.

(2) A very "young-looking" nucleus

The most characteristic features of lymphoblasts include:

- Large nucleus;
- Fine chromatin;
- Prominent nucleoli.

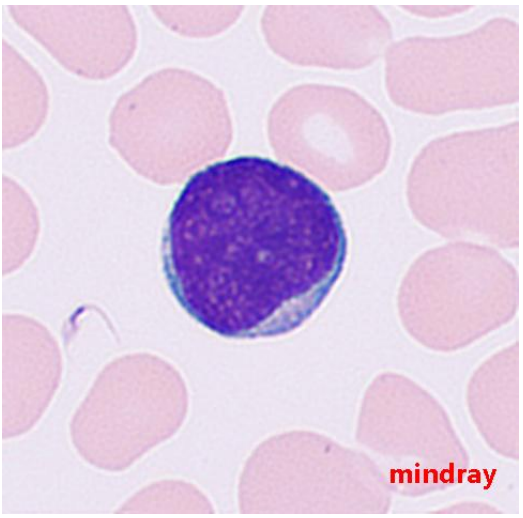

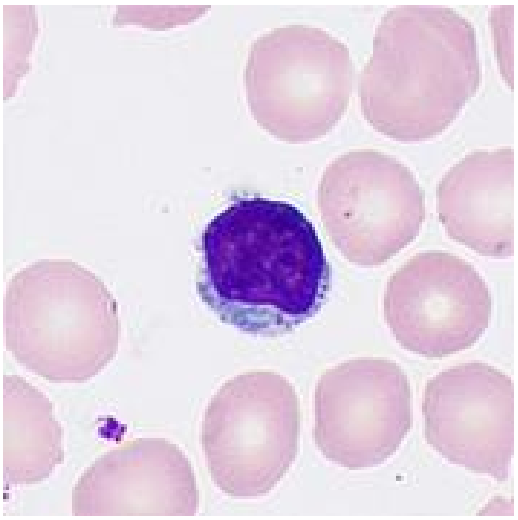

Figure 4: The morphology of Lymphoblasts *Figure 5: The morphology of Lymphocytes*

"Fine chromatin" means that the nuclear material appears loose and delicate rather than condensed.

The presence of visible nucleoli reflects active cellular proliferation.

(3) Scant but deeply basophilic cytoplasm

The cytoplasm is usually dark blue in color and relatively limited in amount.

Granules are generally absent.

How to Remember Lymphoblasts

We can imagine a lymphoblast as a young student who has not fully matured yet.

Like many immature hematopoietic cells, lymphoblasts typically appear:

- Larger in size,
- A relatively large nucleus,
- Fine and loose chromatin,
- An overall immature appearance.

However, these features are not specific to lymphoblasts alone and may also be seen in other types of blast cells.
In peripheral blood smears, lymphoblasts may occasionally appear in small groups, which is mainly related to increased cell numbers rather than a specific clustering pattern.

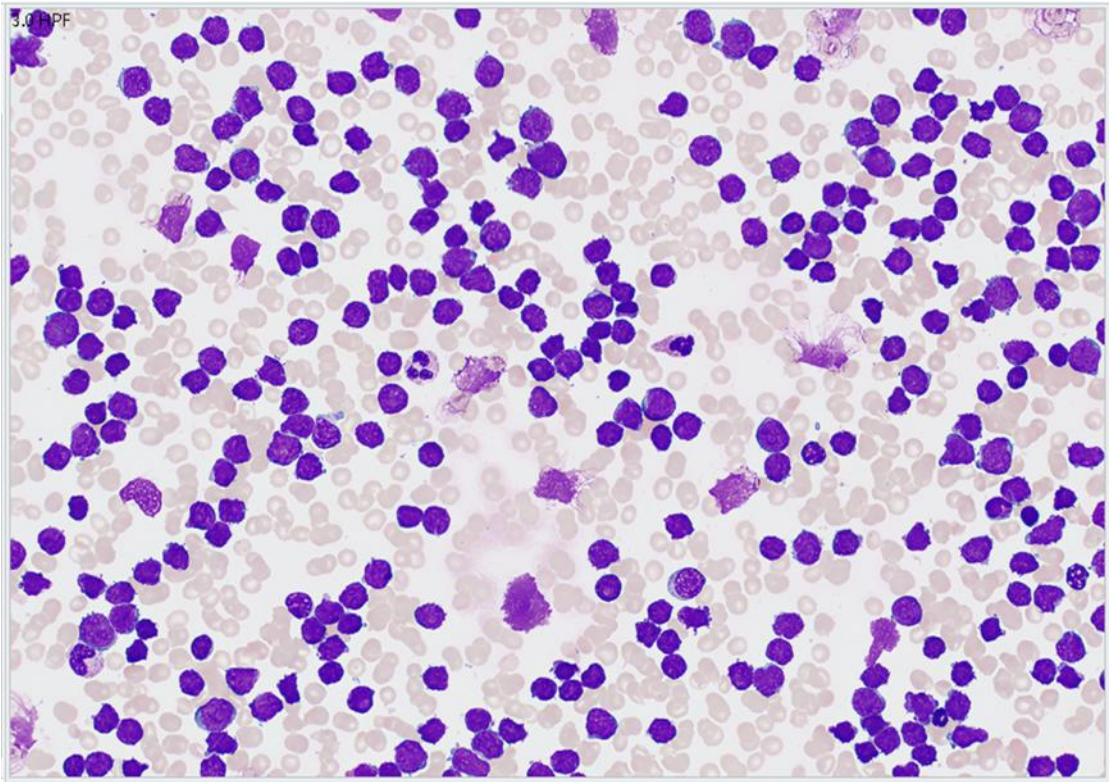

Figure 6: The morphology of Lymphoblasts

III. Prolymphocytes: Cells in Transition
Prolymphocytes represent an intermediate stage between lymphoblasts and mature lymphocytes.
They are no longer as immature as lymphoblasts, but they are not fully mature either.
As a result, they often appear:
"Partially mature."

Morphological Changes During Maturation
Compared with lymphoblasts:
Chromatin becomes coarser
This is one of the most important changes; it indicates progressive maturation of the cell.
In simple terms:
"The cell is beginning to learn how to perform its real job."

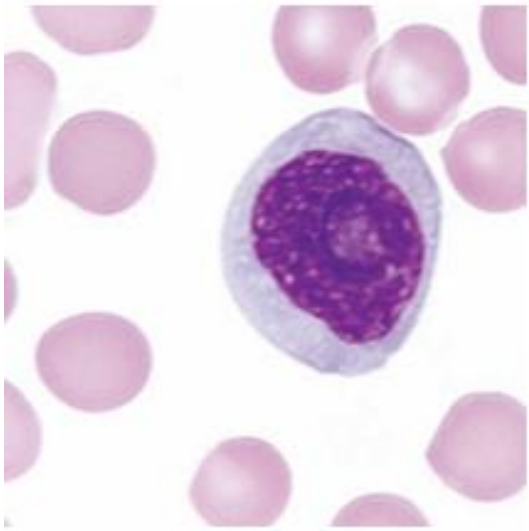

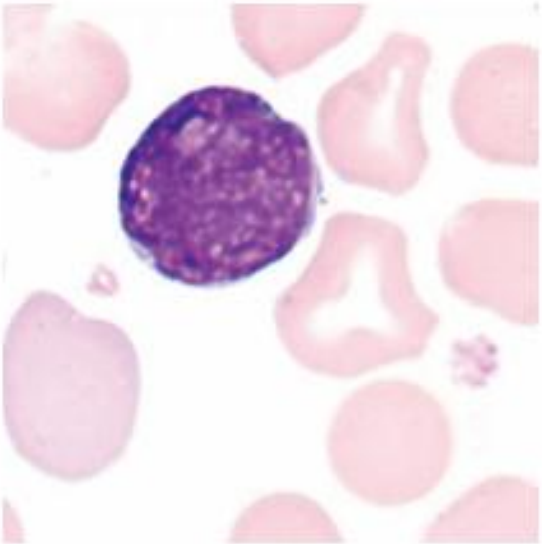

Figure 7: The morphology of Prolymphocytes [1] *Figure 8: The morphology of* Lymphoblasts

- Nucleoli become less obvious because cellular proliferation activity decreases.
- Cell size becomes slightly smaller: although still somewhat larger than mature lymphocytes, prolymphocytes are smaller than lymphoblasts.
- The cytoplasm becomes paler: the amount of cytoplasm slightly increases, while the deep blue staining becomes softer.

IV. T Lymphocytes and B Lymphocytes: Different Specialized Pathways
After maturation, lymphocytes further differentiate into two major functional groups. In peripheral blood smears, T lymphocytes and B lymphocytes are morphologically indistinguishable, as both belong to the population of mature small lymphocytes.

1. T-Lymphocytes
T-Lymphocytes mature in the thymus.

The thymus is a primary organ of the lymphatic system as it serves as a primary site for T-lymphocyte production and maturation during childhood.

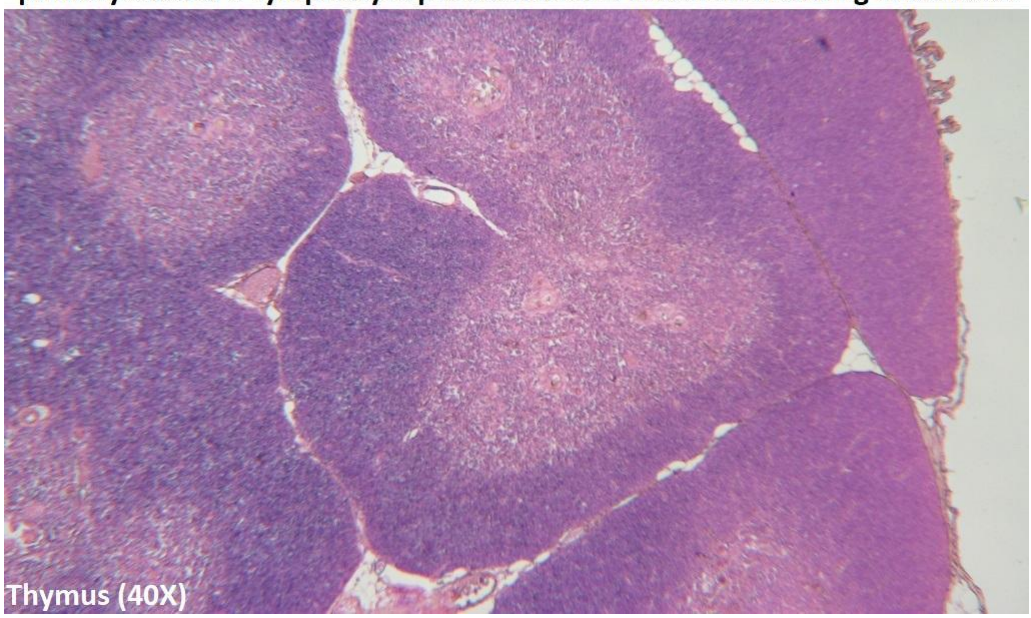

Figure 9: Microscopic section of the thymus[2]
This image shows a microscopic section of the thymus, which is the site where T lymphocytes

are selected.
The outer dark, densely stained region = thymic cortex
The inner lighter, more loosely arranged region = thymic medulla
In the cortex, T cells undergo the first round of selection: only those that can recognize the body's own cells survive, and the qualified T cells move into the medulla.
In the medulla, T cells undergo a second round of selection: only those that will attack foreign viruses and bacteria are retained.
Finally, the successfully selected cells become mature T lymphocytes, leave the thymus, and enter the bloodstream and lymph nodes throughout the body.

They function like "frontline combat units" and are responsible for:

- Directly attacking abnormal cells;
- Eliminating virus-infected cells;
- Regulating immune responses.

For example: When the body is infected by viruses, T lymphocytes are often the cells that directly destroy infected targets.

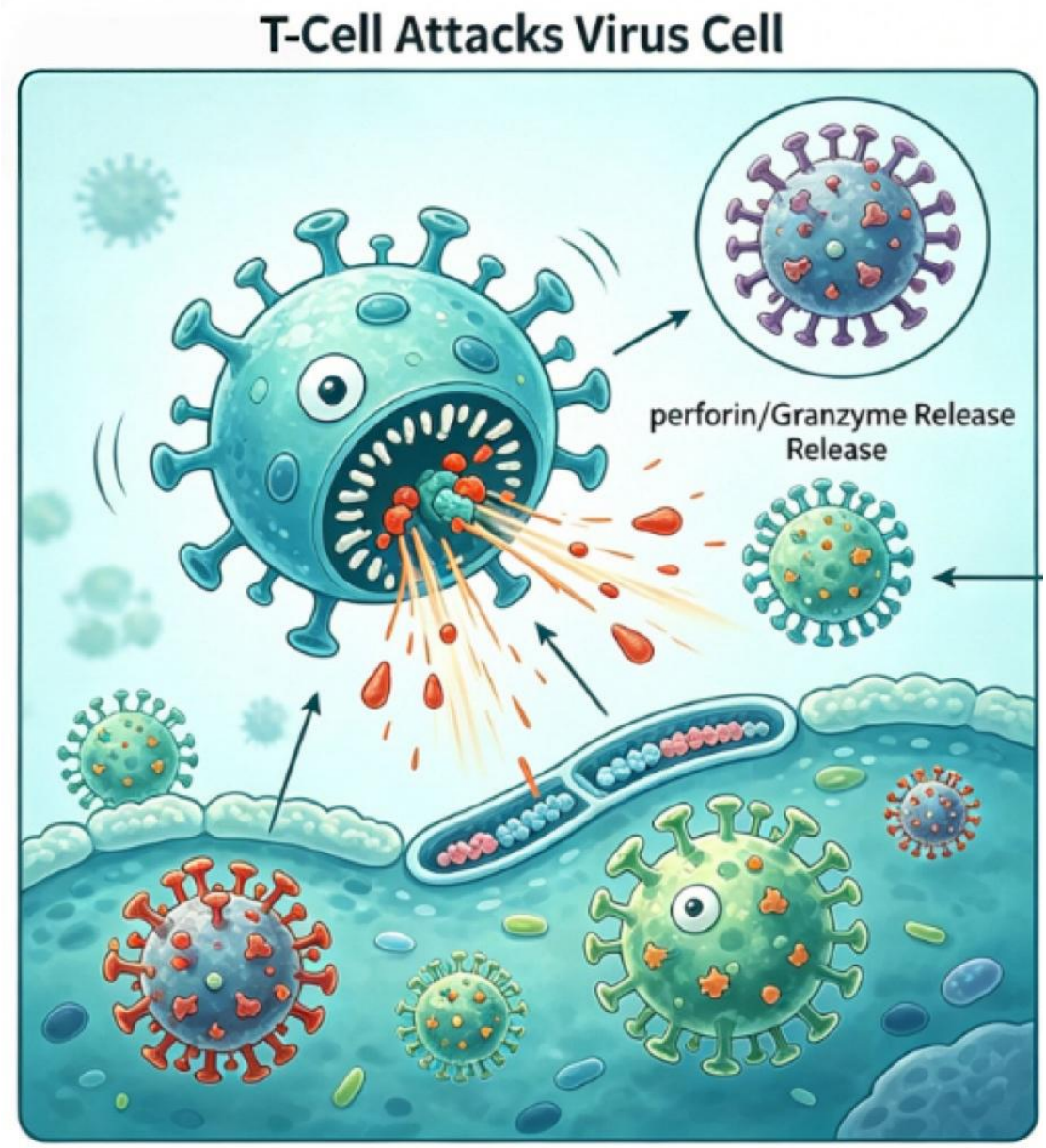

Figure 10: T-Lymphocytes

Because T and B lymphocytes are morphologically indistinguishable, their identification relies on immunological methods such as:
Flow cytometry;

CD marker analysis (e.g., CD3 for T cells, CD19/CD20 for B cells).

2. B-Lymphocytes
B-Lymphocytes function more like an "antibody production department."
Their primary role is: Producing antibodies.
After activation, B lymphocytes can further differentiate into plasma cells and produce large amounts of immunoglobulins.

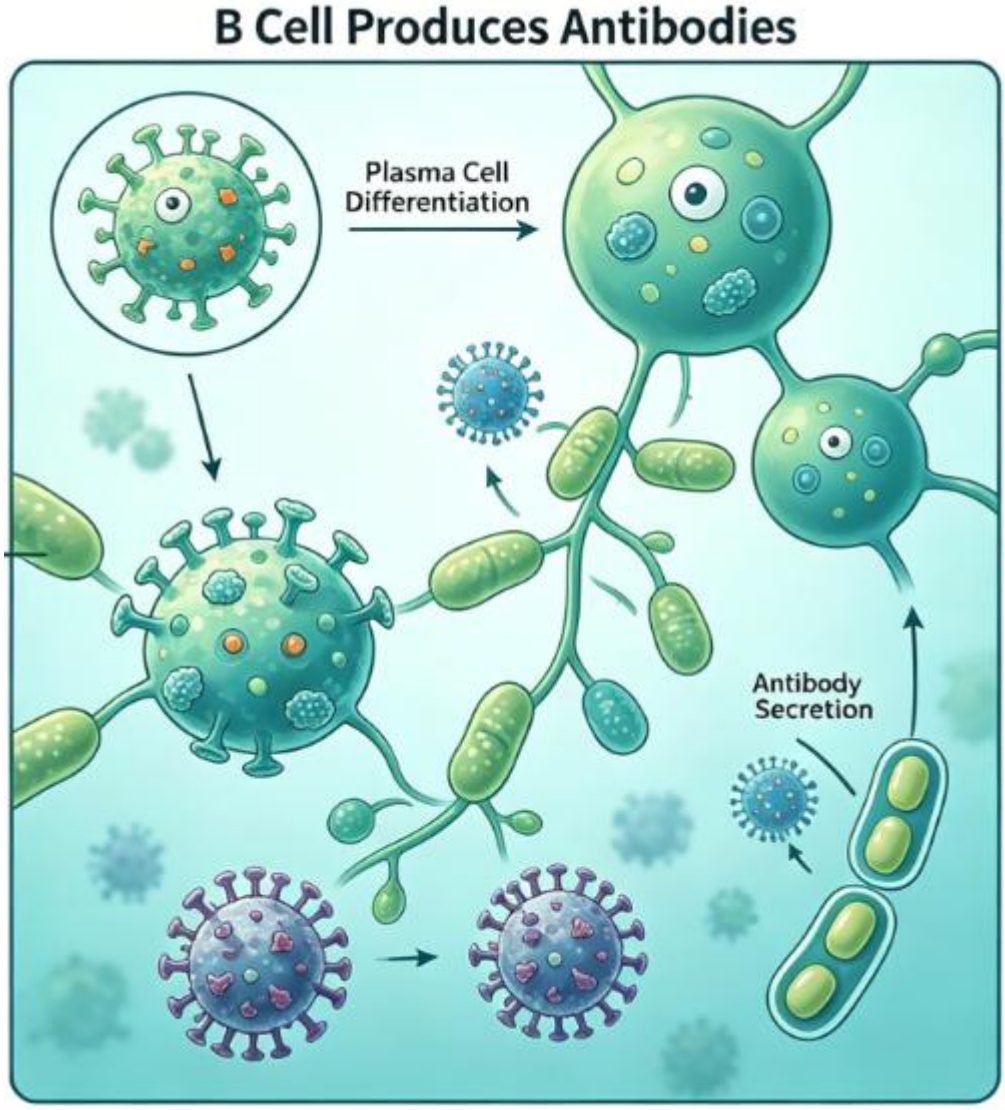

Figure 11: B-Lymphocytes

Morphological Features
Morphologically, they therefore share the typical appearance of small mature lymphocytes in peripheral blood smears.

But upon activation, B lymphocytes may show reactive changes:
- ✧ Increased cell size;
- ✧ More abundant cytoplasm;
- ✧ Stronger basophilia;
- ✧ Occasional plasmacytoid or immunoblast-like morphology.

Because of these overlapping morphological features, immunophenotyping (e.g., CD19 and CD20 expression) is required for definitive lineage identification.

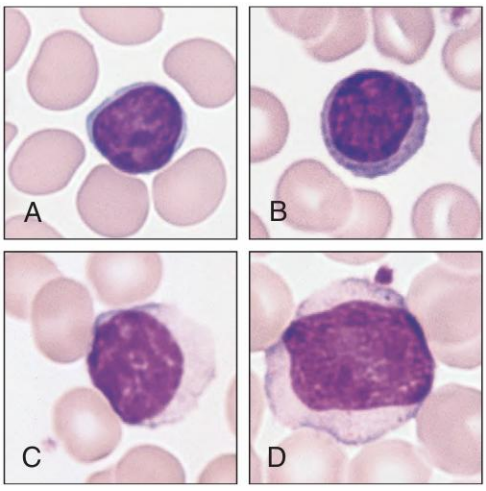

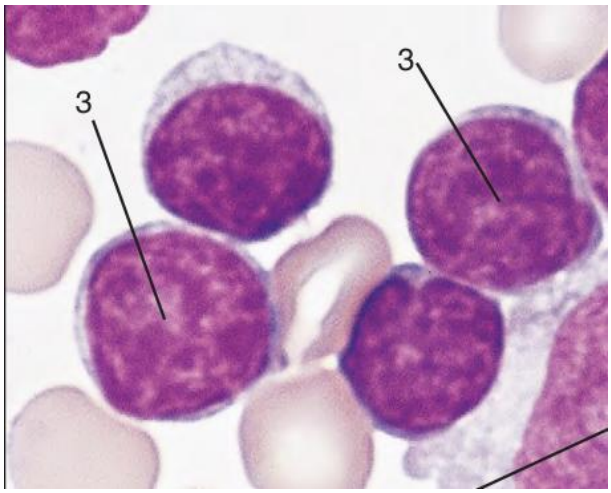

Figure 12: T-Lymphocytes[3] *Figure 13: B-Lymphocytes[3]*

Under routine staining, T lymphocytes and B lymphocytes appear almost identical. The primary method for distinguishing them is immunophenotyping.

V. Morphology of Mature Lymphocytes in Peripheral Blood: The True "Resident Soldiers"

These mature lymphocytes represent the predominant lymphoid cells observed in routine blood films. In healthy adults, lymphocytes account for approximately 20%–40% of total white blood cells.

Figure 14: Mature Lymphocytes

1. Classic Morphological Features of Mature Lymphocytes

(1) Small cell size

Usually around 7–10 μm.

In many cases, they are close to the size of red blood cells.

However, a subset of larger lymphocytes may also be observed in peripheral blood smears. These cells still belong to the mature lymphocyte population and often represent reactive or activated forms rather than a distinct developmental stage.

Compared with small lymphocytes, large lymphocytes typically show:

- Note irregular nucleus
- More abundant cytoplasm than small lymphocytes

(2) The nucleus occupies most of the cell

This is the classic feature of mature lymphocytes.
The appearance is often described as:
"A large nucleus surrounded by only a thin rim of cytoplasm."

(3) Very coarse and condensed chromatin
This is an important sign of maturity.
Compared with lymphoblasts, the nucleus appears:

- ✧ Darker;
- ✧ Coarser;
- ✧ More compact.

(4) Very limited cytoplasm
The cytoplasm usually appears as a thin light-blue rim around the nucleus.

"Large nucleus with scant cytoplasm."

How to Remember Mature Lymphocytes
"Small cell, round nucleus, dark chromatin, thin cytoplasm."
Most normal mature lymphocytes fit this description very well.

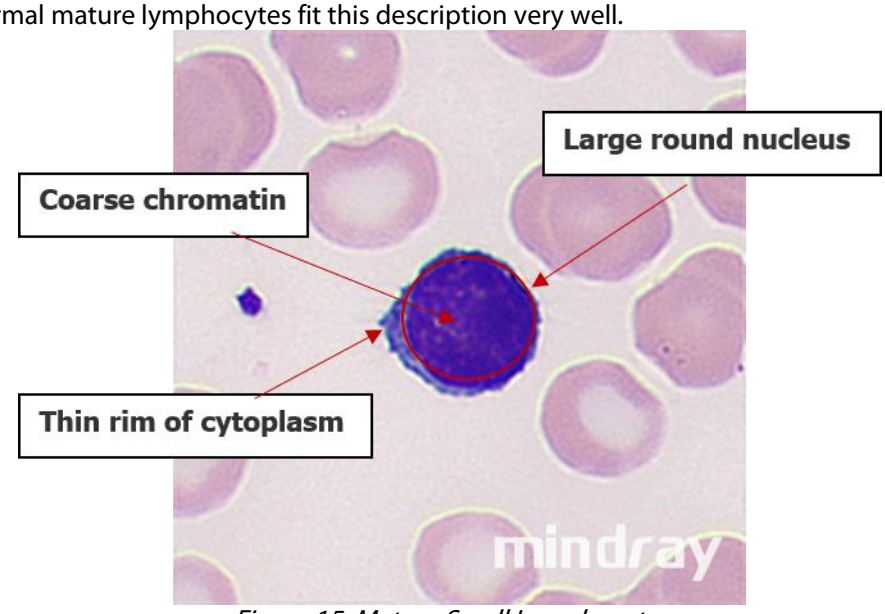

Figure 15: Mature Small Lymphocytes

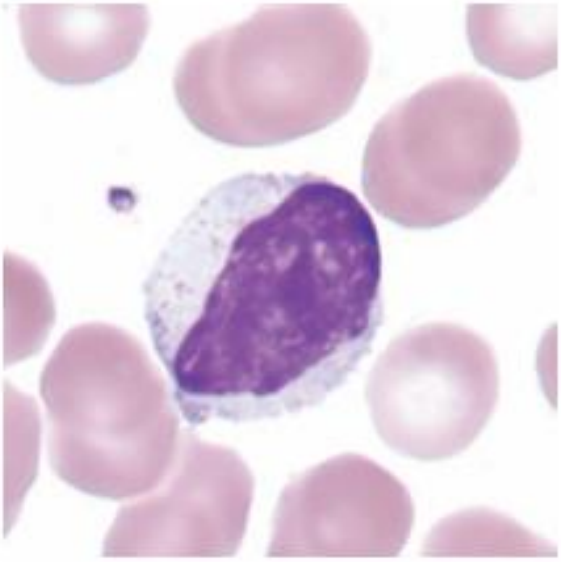

Figure 16: Large lymphocyte. Note the irregular nucleus and more abundant cytoplasm than small lymphocytes

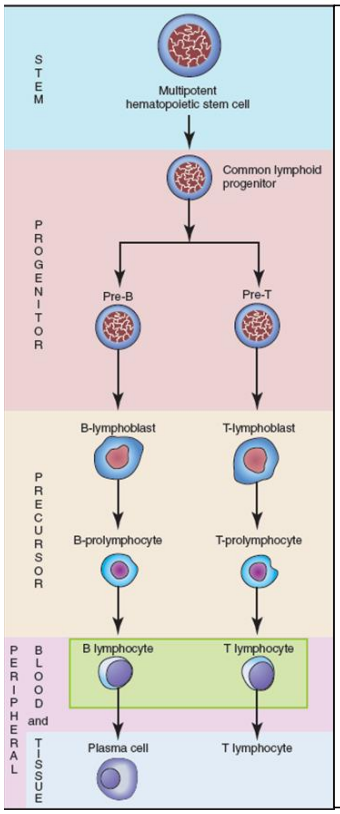

Immature Lymphocytes case from Mindray hematology analyzer:

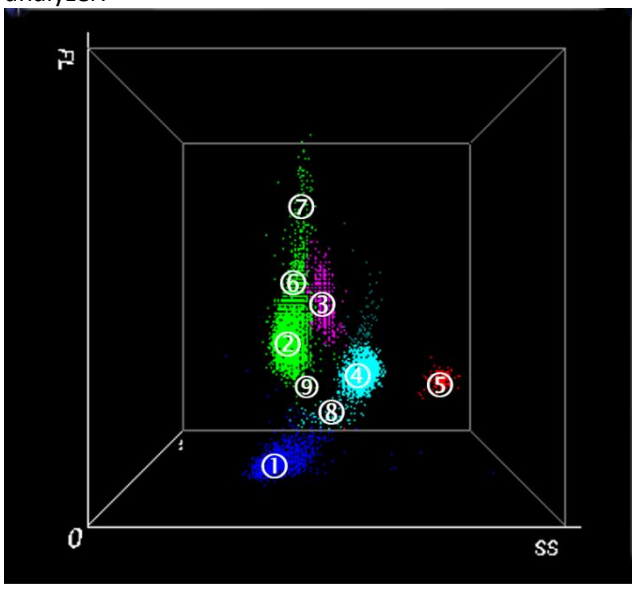

①Ghost ②Lymphocyte ③Monocyte④Neutrophil ⑤ Eosinophil ⑥Blast ⑦High fluorescence cell (reactive lymphocyte & blast, etc.) ⑧Basophil ⑨Nucleated RBC

Figure 17: SF-Cube

STAT	Para.	Flag	Result	Delta(#)	07-11	07-10	Unit
	WBC	H	14.48	3.450	11.03	9.35	10^3/uL
	Neu%	RL	31.7	-6.30	38.0		%
	Lym%	RH	61.6	9.50	52.1		%
	Mon%	R	4.6	-2.40	7.0		%
	Eos%		1.2	-0.60	1.8		%
	Bas%		0.2	0.00	0.2		%
	IMG%	R	0.7	-0.20	0.9		%

Mature lymphocytes are usually located in region 3. According to the characteristics of the SF-Cube, the more immature the cells are, the higher their position on the FL axis. Therefore, compared with mature lymphocytes, immature lymphocytes show higher FL values, with the order being:
Mature lymphocyte < Prolymphocyte < Lymphoblast

VI. The Most Important Concept in Morphology Learning
The more immature the cell:
- ✧ The larger it is;
- ✧ The finer the chromatin;
- ✧ The more visible the nucleoli;
- ✧ The deeper blue the cytoplasm.

The more mature the cell:
- ✧ The smaller it becomes;
- ✧ The coarser the chromatin;
- ✧ The nucleoli disappear;
- ✧ The cytoplasm decreases.

This concept can be summarized as:
"Immature cells look delicate; mature cells look condensed."

VII. Summary
Normal lymphocyte development is a gradual maturation process:
Lymphoblasts: delicate chromatin and prominent nucleoli;
Prolymphocytes: an intermediate maturation stage;

Mature lymphocytes: condensed chromatin and scant cytoplasm;
In peripheral blood, mature lymphocytes represent a morphologically uniform population that corresponds to both T and B lymphocyte lineages, which cannot be distinguished by light microscopy.

For beginners studying morphology, the most important goal is not to memorize every detail immediately, but to understand:
"How cells change during maturation."
Once this developmental pattern becomes familiar, recognizing abnormal lymphocytes, reactive lymphocytes, or leukemic cells will become much easier.

Quick- Reference Table: Key Identifiers

Cell Type	Cell Size	Nuclear Features	Chromatin	Nucleolus	Additional Features
Lymphoblasts	Large	Round or oval, regular	Fine, loose, lightly stained	Prominent (1–3 nucleoli)	High proliferative activity
Prolymphocytes	Medium to large	Slightly irregular	More condensed than lymphoblasts	Usually one visible nucleolus	Between blast and mature cells
Mature lymphocytes	Small	Round, regular	Dense, clumped (dark purple)	Not visible or absent	Common in peripheral blood

References & Image Sources

References:
1. Clinical Hematology Atlas, Fourth Edition- Bernadette F. Rodak.
2. Thymus: Histology, features, cell types, and anatomy
3. Color Atlas of Clinical Hematology

Images & Technical Support: Most morphology images in this course are derived from analysis by the Mindray automated digital morphology analyzer MC-80.

Practice

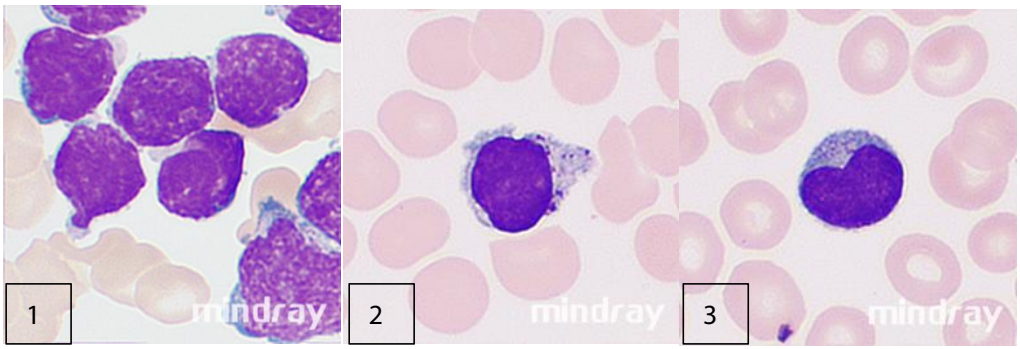

[The answers will be at the end of the next chapter]

The answers to the last chapter: 1. Promyelocyte; 2. Segmented neutrophil; 3. Monocyte; 4. Basophil; 5. Metamyelocyte; 6. Myelocyte

Author

Kiki Yang
— Clinical Application Specialist

— ***Coming Next: Qualitative abnormalities in myeloid cells-Cytoplasmic abnormalities***—